

# Thursday, February The 5<sup>TH</sup> 2009

## How to get esthetics in implantology ?

I.1 ZHDANOV EVGENY

Russia



In 1989, he graduated from Moscow State Stomatological Institute and from 1989 to 1991 attended a 2-year postgraduate training course (clinical residency) in surgical dentistry in Moscow District Scientific Research Institute (named after Vladimirsky).

From 1991 to 1997 Dr. Zhdanov worked as a research fellow in the above-named institute.

Since 1997 he has been a founder, owner, chief dentist and chief dental surgeon of DOMODENT dental clinic.

In 2003 Dr. Zhdanov defended his dissertation and received a degree of candidate of medical sciences.

For many years he has been performing dental implantation and bone reconstructive surgery.

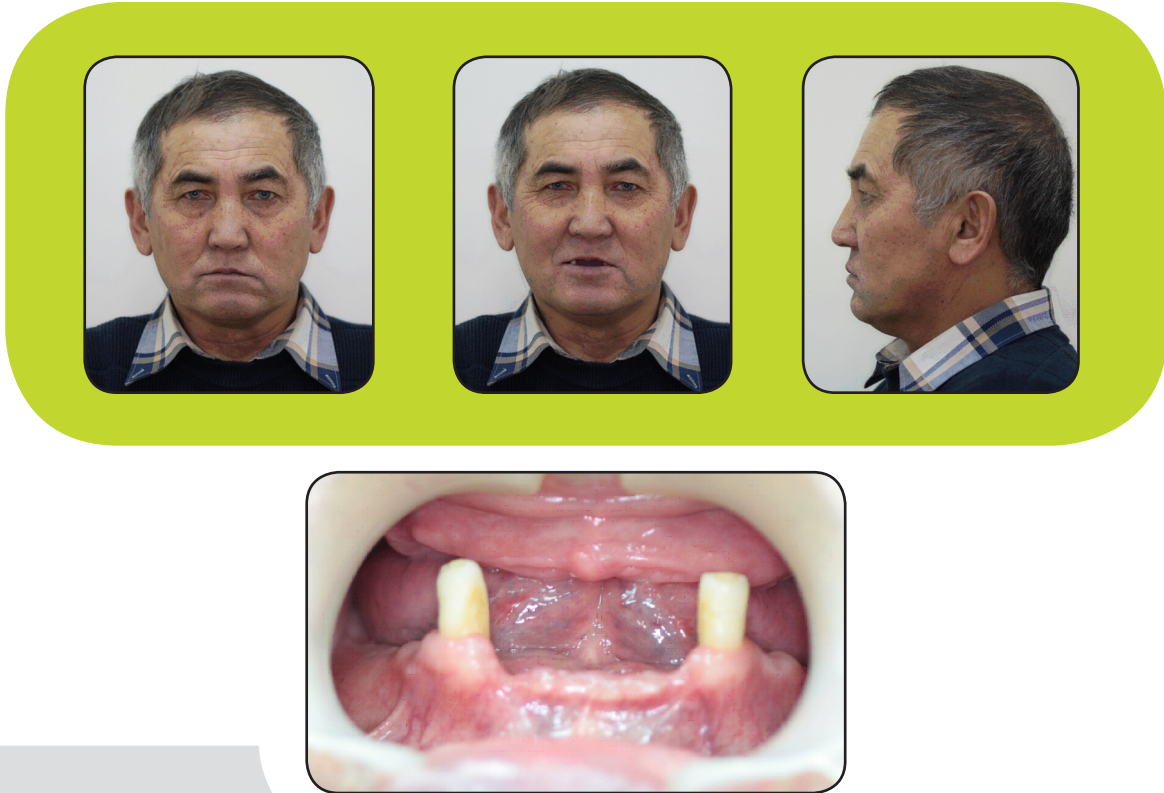Since 2001 he has been using ANTHOGRYR implant systems.

Presentation :

### **The Innovative approach to the Treatment of Total Edentulism and Advanced Maxillary Alveolar Atrophy.**

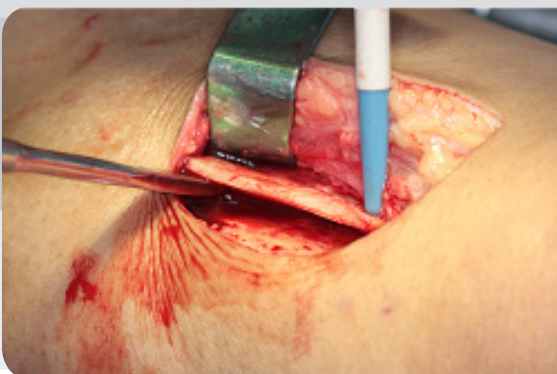
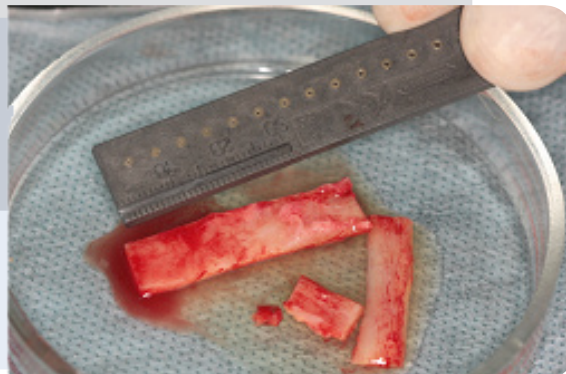
A clinical case about the surgical preparation and prosthodontic treatment of total edentulism and advanced bone atrophy followed by alveolar reconstruction with tibial autografts and Anthofit implant-supported removable prosthesis on telescopic crowns and a zirconium framework (with the use of CAD/CAM technique and galvanoplasty).

A 56-y.o. male patient presented himself at our clinic on the 31st of January, 2008, for prosthodontics. The patient was a non-smoker and otherwise healthy. In the maxilla, 3 remaining teeth were mobiles (grade III) and extracted. In the mandible, both canines remained. In the maxilla, the alveolar process had Division C or D atrophy (according to 1985 Misch & Judy classification). In the mandible, Division B atrophy was observed. Jaw relationship in the sagittal plane was classified as pseudo-class III malocclusion (Fig. 1).

**Fig.1**

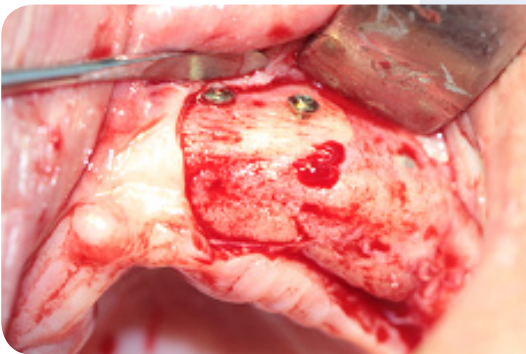
After physical/lab examinations, preliminary wax-up and computerized exam, the tooth roots were extracted and 8 Anthofit implants inserted in the mandible to seat a fixed ceramic-to-metal prosthesis. During the implant insertion, Kazanian vestibuloplasty was performed in the anterior mandible. (The prosthesis was made 4 months later).

To perform implant insertion, alveolar reconstruction with tibial cortical grafts (in the form of bone blocks and chips) and bilateral sinus-lifts with Bio-Oss grains were performed. For augmentation, the vestibular approach with elements of tunnel technique was used. The recipient and donor sites healed with primary intention. (Fig. 2, 3, 4)

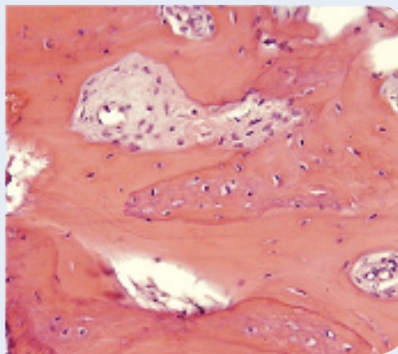
**Fig.2****Fig.3**

In the maxilla, 6 implants were inserted to seat a fixed prosthesis on telescopic crowns.

During implants insertion, the repaired bone had good vascularization and no signs of resorption. (Fig. 4) Repaired bone morphology stained with hematoxylin-eosin showed that grafted bone tissue was viable; it contained viable osteoblasts and osteocytes. At the periphery of the grafted bone young bone rods were being formed. (Fig.5)

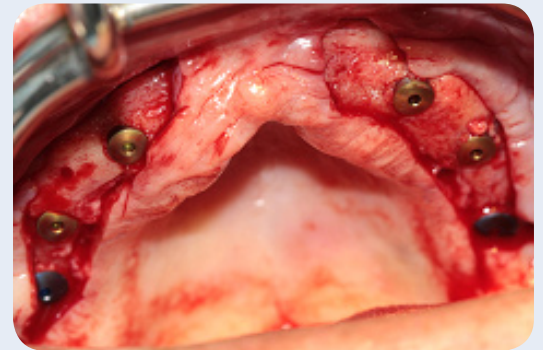


**Fig.4**



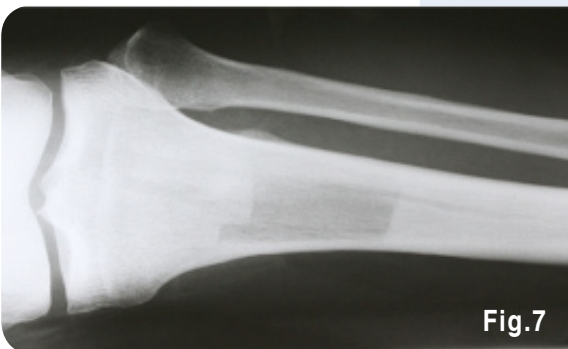**Fig.5**

4-mm Anthofit implants with internal octagonal connection were inserted in positions 1.3, 2.3, 2.5 and 5-mm in positions 1.7 and 2.7 at 5 months after grafting. (Fig. 6)

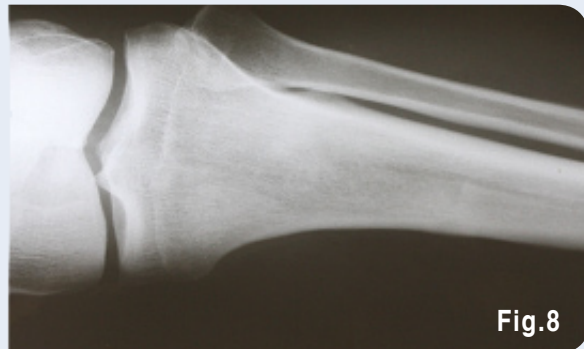

**Fig.6**

On tibial X-rays 6 months later complete bone repair was seen. (Fig. 7, 8)



**Fig.7**



**Fig.8**

The implant uncoverly was performed 4 months later, with gingivoplasty by means of a free palatal epithelial flap split in the shape of mesh. Due to soft tissue surgery, implant abutments were surrounded with the dense attached keratinized gingiva. (Fig. 9)

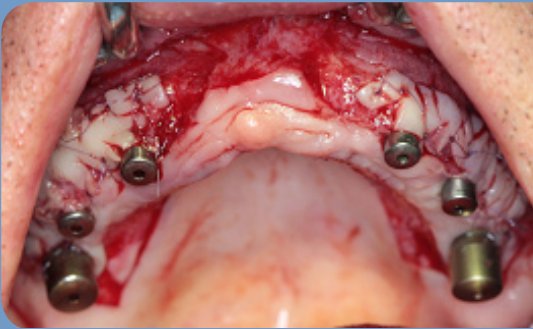


Fig.9

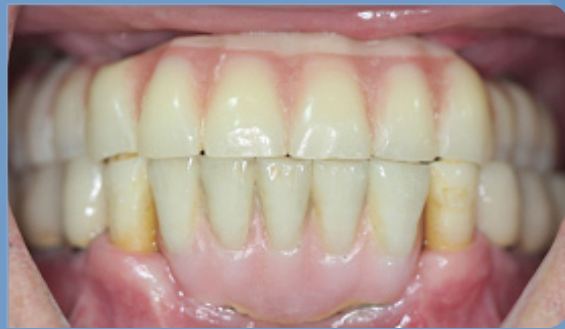

Fig.10

Four weeks after the uncover surgery, prosthodontics in the maxilla began.

For provisional prosthodontic, interim abutments (implant carriers) with external hexagonal connection were used. The fabricated removable prosthesis was adapted to the inserted abutments. Due to the provisional restoration, the patients received fixed interim prosthesis soon after the uncover surgery (Fig. 10). During the fabrication of final prosthesis, the patient was rehabilitated prosthodontically.

For a final restoration, straight "Tin-plus" abutments with the collar height of 1 mm were chosen. To select abutments, orthopedic platform switch technique was used. The abutments were machined in a surveyor. Zirconium frameworks for the implant abutments were fabricated and machined with a dental turbine in the surveyor with an angle of  $2^\circ$  (Fig. 11).

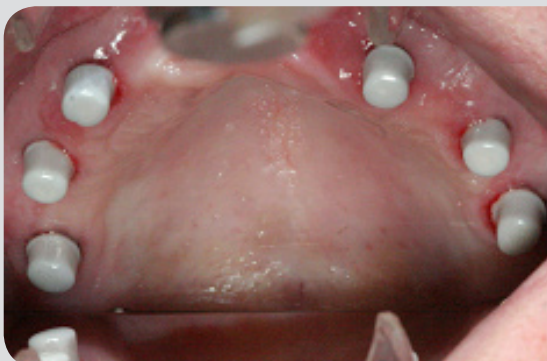

Fig.11

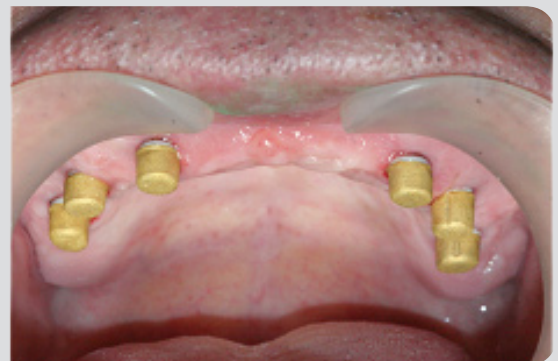

Fig.12

In "AGC Micro Weiland" machine, galvanic caps for zirconium frameworks were fabricated (Fig.12). A tertiary framework made of chromium-cobalt-based alloy was fabricated to place on the galvanic caps. The zirconium frameworks were cemented to the implant abutments with "Fuji+" cement. The tertiary framework was stuck to the galvanic caps with "Nimetic Cem" 3M Espe. (Fig.13) The centric relation was determined. The restoration was checked in the oral cavity. Then, the final prosthesis was fixed (Fig.14-17).

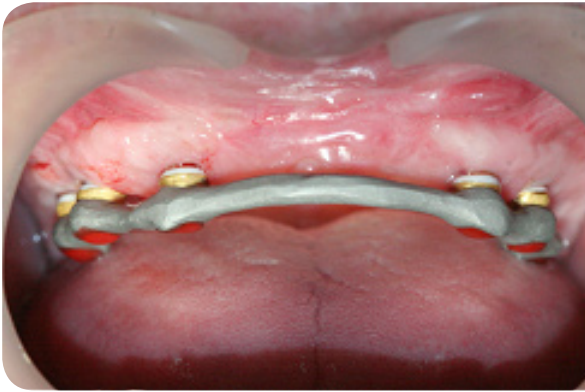


Fig.13

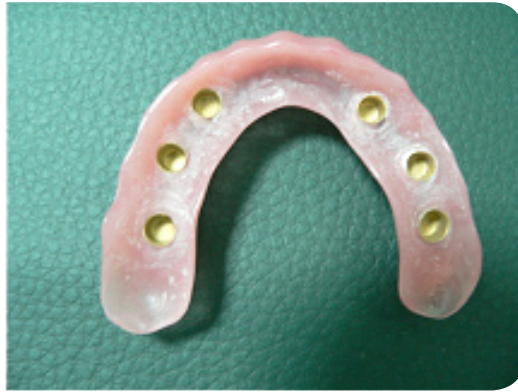

Fig.14

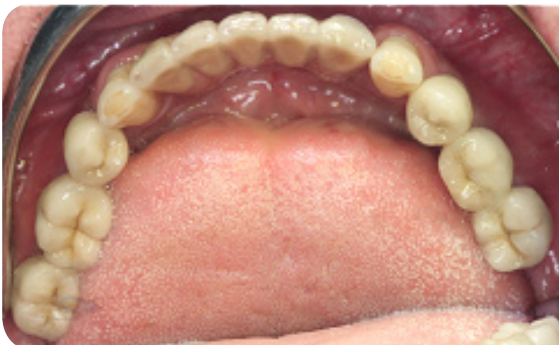

Fig.15

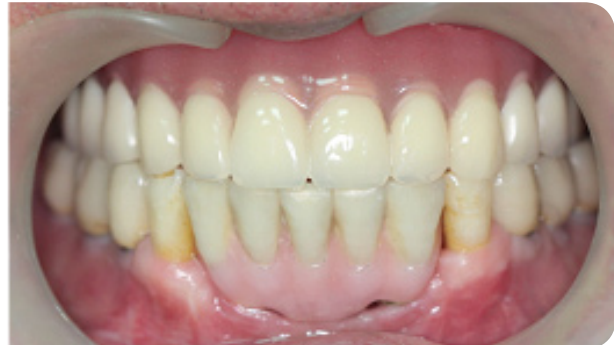

Fig.16

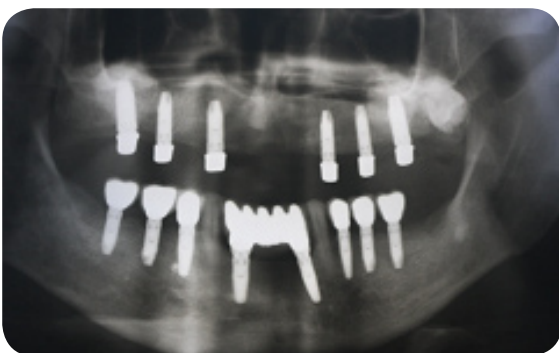

Fig.17

#### Publications:

1. Zhdanov EV et al. The use of depot phoresis of copper-calcium hydroxide for the treatment of impassable and hard to reach root canals. *Stomatologiya (Mosk)*. 2002;81(4):61-3
2. Nikitin AA, Kazantseva IA, Zhdanov EV, Kosiakov MN et al. The use of bioceramic materials and cryosurgery in the treatment of patients with the Gorlin-Goltz syndrome. *Stomatologiya (Mosk)*. 1997;76(6):35-7